

# Abdominal Compartment Syndrome: Case Report

*Ricardo Fernández, Angel Galera, Pablo Rodríguez, William Rodriguez*

## Abstract

Abdominal compartment syndrome (ACS) was originally described in trauma patients but is now known to occur in critically ill patients with a myriad of acute illnesses. Recent epidemiological studies have characterized the prevalence of intraabdominal hypertension (defined as an intraabdominal pressure [IAP] measured at the urinary bladder  $\geq 12$  mmHg) between 2% and 33% [1,2] and the prevalence of ACS (defined as an IAP  $\geq 20$  mmHg and associated organ system dysfunction) between 1% and 15%. These prevalences are similar to those quoted for sepsis and septic shock in trauma patients.

Multiple studies have shown that massive fluid resuscitation is the most common risk factor for ACS.

The rise in intraabdominal pressure causes worsening of the capillary leak as a consequence of their primary illness, further decreasing vital organ perfusion and resulting in multiple organ dysfunction syndrome (MODS). Management includes hemodynamic support and abdominal decompression. Because of its protean manifestations, a high index of suspicion and frequent monitoring of the IAP in high-risk patients are the best preventive measures.

Our case report shows the clinical features of a patient with ACS. The diagnosis was made early in the clinical source, yet appropriate management was deferred because of the uncertainty management in this critically ill patient.

**Key words:** Abdominal Compartment Syndrome, pathophysiology, measurement

## Case report

A 57 y/o diabetic man with atrial fibrillation on chronic anticoagulation and chronic renal insufficiency came to our center complaining of progressive increase in shortness of breath.

The patient was afebrile, normotensive with juguloenous distention, poor inspiratory effort, bibasilar inspiratory crackles, a 4/6 apical holosystolic murmur and S3 gallop. The abdomen was distended and tense, and an ascitic wave was present. There was (+3) pitting edema on both legs.

The patient was treated for pulmonary edema with oxygen, IV diuretics and IV nitrates. A therapeutic paracentesis yielded 2 L of yellow clear fluid; empiric treatment with cefotaxime was started for suspected spontaneous bacterial peritonitis.

The patient remained dyspneic despite treatment; hydralazine was discontinued and metolazone and captopril were started. An echocardiogram was essentially unchanged from prior studies. Overt respiratory failure ensued on the 7th day of hospitalization and the patient was intubated and mechanically ventilated. A repeat paracentesis was done in an effort to improve the mechanical restriction to lung movement; bloody fluid was aspirated and the procedure was aborted. Laboratory data showed a fall in Hb from 11.5 to 5.5 g/dL. Warfarin was discontinued and the patient was transfused with packed red cells and plasma. Nasogastric aspirate and stool were both negative for occult blood. An emergency abdominal

---

From Pulmonary and Critical Care Medicine Training Program  
VA Caribbean Health Center, San Juan Puerto Rico (Drs. Ricardo  
Fernandez, Angel Galera, Pablo Rodriguez, William Rodriguez).

**Address all reprints to:**  
Ricardo Fernández, MD  
VA Caribbean Health Center  
10 Casia Street, 111-E OPA Building  
San Juan, PR 00927-5800  
serser@pol.net

CT scan showed massive ascites. The patient continued to deteriorate and was transferred to the intensive care unit.

In the ICU, resuscitation continued with blood and plasma transfusions as well as large amounts of isotonic crystalloids for hypotension. Clinically, the patient was oliguric and hypoxemic with peak airway pressures higher than 40 cmH<sub>2</sub>O. Abdominal compartment syndrome was suspected; the intraabdominal pressure (IAP) measured at the level of the urinary bladder was 30 mmHg, confirming the diagnosis. A tagged RBC scan suggested a left sided abdomino-pelvic actively bleeding site at the area of the iliac artery bifurcation. Surgical consultation was obtained but the patient was felt to have developed rapidly progressive acute multiorgan dysfunction syndrome including cardiovascular, respiratory and renal, and that he would not tolerate an exploratory laparotomy or acute vascular surgery. The patient died of ongoing intractable hypotension the following day. Massive bleeding into the peritoneal cavity (Figure 1) due to paracentesis needle puncture and midpsoas (Figure 2) were the presumed causes of the ACS, etiology of this patient final demise.

## Discussion:

Normal intra-abdominal pressure (IAP) is 0 mmHg during spontaneous breathing [3]; minimal increases in IAP have been described in patients on mechanical ventilation, thought to be related to transmission of positive intra-thoracic pressure through the diaphragm. In critically ill patients with systemic hypoperfusion and shock, an IAP of 15 mmHg is not uncommon.

Abdominal compartment syndrome (ACS) occurs when an elevated IAP causes a decrease in perfusion pressure of the abdominal organs. Clinical manifestations include hypotension, tachycardia, a tense abdomen, increased ventilatory requirements, elevated airway pressures and oliguria. The leading cause is massive volume resuscitation; other etiologies include neoplasm, pancreatitis, massive ascites, peritonitis, and bowel obstruction. The pathophysiology of this condition is related to an increase in capillary leak leading to fluid sequestration in the abdominal cavity, with concomitant increased intraabdominal pressure causing inadequate tissue perfusion. Under normal circumstances, the abdominal wall compliance limits an increase in

intraabdominal pressure; ACS is thus a late manifestation of persistent and uncontrolled intraabdominal hypertension. Moreover, a high intraabdominal pressure causes a rise in intrathoracic pressure by elevating the diaphragm and restricting its excursion, with attendant cardiac compression, vasoconstriction and reduced ventricular compliance. These effects lead to a drop in venous return and increased peripheral resistance, resulting in a significant reduction in cardiac output, which further contributes to vital organ hypoperfusion. The series event, if not identified or treated appropriately may lead to multiple organ failure (Figure 3).

Critically ill patients, especially those in surgical intensive care units are at risk of developing this condition. Unfortunately, affected patients are severely ill and often signs of organ failure are attributed to the primary illness, so that ACS is not entertained as a potential confounding factor affecting vital organ function. Despite advances in the diagnosis and treatment, mortality rate remains high, between 50-100% [3,4]. Early diagnosis is imperative in the management of patients with suspected ACS. Two common methods are available for measuring IAP: the direct method, placing a catheter directly into the peritoneal cavity, and the indirect method, where the pressure inside the urinary bladder is measured. The latter method has been found to reliably reflect IAP. After appropriate calibration by placing a pressure transducer at the level of the symphysis pubis, 50 ml of saline is injected through a foley catheter and the pressure is measured [5]. Maxwell et al recommended monitoring intraabdominal pressure in patients who have received either 10 U of PRBC or 10 L of fluid resuscitation [6] and Biffi et al suggested that IAP should be measured every 2 to 4 hours in high risk patients [7]. Although definitive management of ACS is abdominal decompression, the patient's circulation should be supported with vasoactive drugs and appropriate ventilation until surgical intervention can be performed safely. Many physicians believe that ACS occurs exclusively in trauma or surgical critical illness. There are fewer published cases of ACS in medical patients; we believe the most likely explanation for this lack of knowledge among clinicians is an inability to identify the clinical signs and symptoms associated with the syndrome.

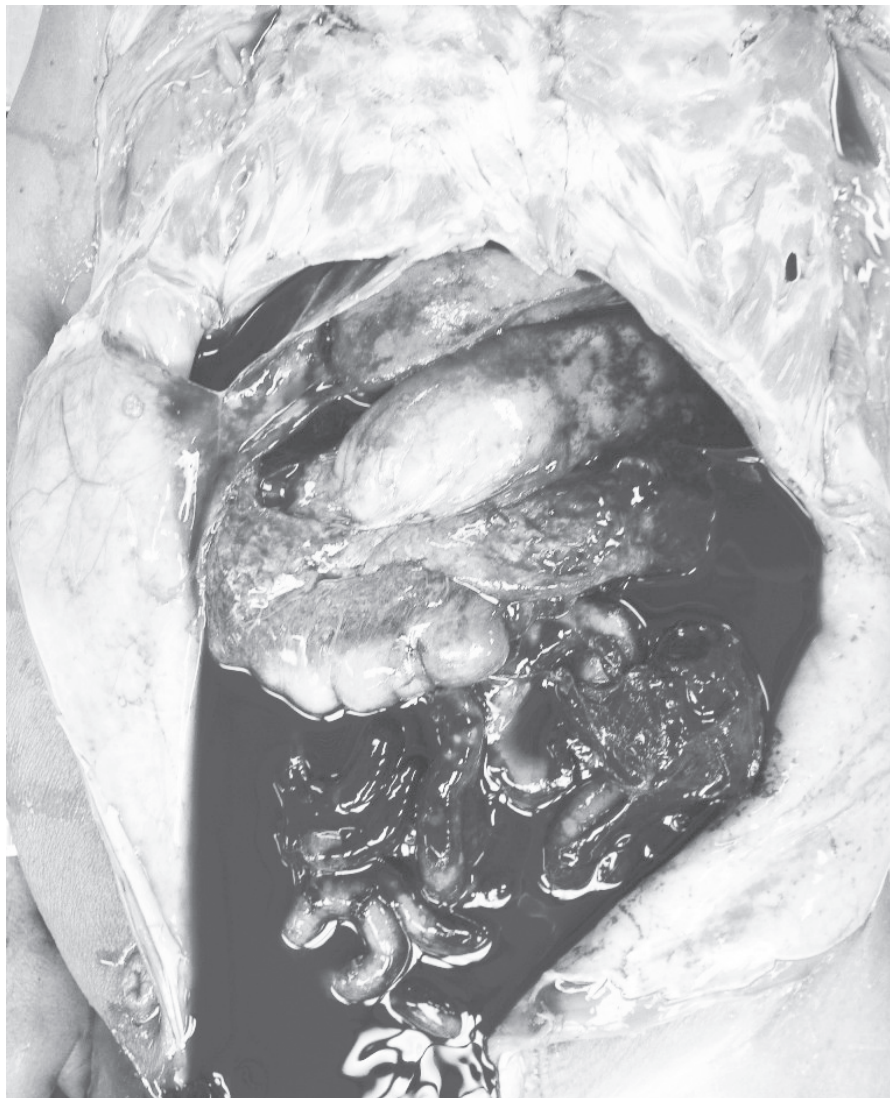
In our case the patient developed rapidly progressive multiple organ dysfunction after massive fluid

resuscitation; moreover, he bled into the peritoneal cavity. Unfortunately, due to the severity of his acute illness and his multiple comorbidities, surgical decompression was not performed.

ACS represents an increasingly recognized cause of significant morbidity and mortality in the critically ill.

Failure to identify intra abdominal hypertension and ACS is associated with extremely high mortality rates. A high index of suspicion, aggressive monitoring of patients at risk for ACS, and early intervention are the better ways to reduce this high mortality.

**FIGURE 1:** AUTOPSY RESULTS SHOWING BOWEL DISTENTION AND MASSIVE BLEEDING INTO THE PERITONEAL CAVITY





## CLINICAL MANIFESTATIONS

Hepatic	Extrinsic compression leads to ↓ hepatic and portal vein flow ↓ cardiac output leading to ↓ hepatic artery flow and lactic clearance
Gastrointestinal	↓ celiac and mucosal flow which leads to bowel ischemia and systemic metabolic acidosis
Central Nervous System	Increased intrathoracic/intra abdominal pressures impair cranial venous return and decreases cerebral venous flow
Renal	↓ urinary flow (one of earliest signs), renal artery blood flow and glomerular filtration flow
Cardiovascular	Hypovolemia ↓ venous return and cardiac output ↑ Pulmonary Capillary Wedge Pressure (PCWP)
Pulmonary	↑ intrathoracic pressure, inspiratory pressure and airway pressure ↓ compliance and hypoxemia

## IAH GRADING SYSTEM AND RECOMMENDED MANAGEMENT (proposed by Burch [8,9])

Grade	Bladder pressure (cmH <sub>2</sub> O)	Surgical management
I	10-15	No
II	15-25	Based on patient condition
III	25-35	Decompression
IV	≥35	Immediate decompression

## References:

- Hong JJ, Cohn SM, Perez JM, Dolich MO, Brown M, McKenney MG (2002) Prospective study of the incidence and outcome on intra-abdominal hypertension and the abdominal compartment syndrome. *Br J Surg* 89:591-596
- Ivatury RR, Porter JM, Simon RJ, Islam S, John R, Stahl WM (1998) Intra abdominal hypertension after life-threatening penetrating abdominal trauma: prophylaxis, incidence and clinical relevance to gastric mucosal pH and abdominal compartment syndrome. *J Trauma* 44:1016-1021
- Bailey J, Shapiro MJ (2000) Abdominal Compartment Syndrome. *Crit Care* 4:23-29
- Sugrue M (2005) Abdominal compartment syndrome. *Curr Opin Crit Care* 11:333-338
- Malbrain ML (2004) Different techniques to measure intra-abdominal pressure (IAP): time for a critical re-appraisal. *Intensive Care Med* 20:357-371
- Maxwell RA, Fabian TC, Croce MA, Davis KA (1999) Secondary abdominal compartment syndrome: an underappreciated manifestation of severe hemorrhagic shock. *J Trauma* 47:995-999
- Biffi WL, Moore EE, Burch JM, Offner PJ, Franciose RJ, Johnson JL (2001) Secondary abdominal compartment syndrome is a highly lethal event. *Am J Surg* 182:645-648
- Sieh KM, Chu KM, Wong J (2001) Intraabdominal hypertension and abdominal compartment syndrome. *Langenbecks Arch Surg* 386:53-61
- Burch JM, Moore EE, Moore FA, Franciose R (1996) The abdominal compartment syndrome. *Surg Clin North Am* 76:833-842