

# Repeated acute respiratory failure: the strongyloidiasis hyperinfection syndrome

*Salim Surani, Mauricio Rodriguez, Sophia Nooruddin, Joseph Varon*

## Case presentation

A 63 year-old gentleman with a history of mitral valve repair and recent travel to the Philippines presented to our hospital with complaints of dry cough for three days. His clinical exam was remarkable for diffuse rhonchi. Initial chest radiograph was non-revealing. The patient clinical condition deteriorated in the emergency department (ED) with rapidly progressive respiratory insufficiency and interval development of radiographic infiltrates (Figure 1). The patient was then admitted to the intensive care unit (ICU) and broad-spectrum antibiotics started.

As the patients' symptoms and radiological findings worsened bronchoscopy and bronchoalveolar lavage were emergently performed. The later yielded no organisms. A transbronchial biopsy was non diagnostic. An open lung biopsy was performed and consistent with bronchiolitis obliterans organizing pneumonia (BOOP). Again, all cultures were negative and no organisms seen. The patient was started on intravenous corticosteroids with an excellent clinical response and two days later was extubated.

**Key words:** Parasitic lung infection, hyperinfection syndrome, strongyloidiasis.

Two weeks after his initial admission to the hospital, while in a long-term acute care facility, the patient complained of dyspnea on exertion and a new bilateral lower extremity erythematous rash. The patient had a repeat chest radiograph revealed diffuse bilateral lung infiltrates. The patient's condition worsened and required re-intubation and assisted mechanical ventilation over next twelve hours. A repeat bronchoscopy with BAL this time revealed *Strongyloides stercoralis* (Figures 2 and 3).

## Discussion

*Strongyloides stercoralis* is an intestinal nematode of humans. It is endemic in tropical and subtropical regions. Its prevalence is very variable even within the particular geographical area. It is estimated that millions of people worldwide are infected, but the precise estimate is unavailable. (1) Prevalence of up to 25% has been reported in some countries. (2) Strongyloidiasis is endemic in tropical and subtropical regions and occurs sporadically in temperate areas. In United States, it mainly occurs among the residents of southeastern states, and among individual who have been in endemic area as immigrants, travelers and military personnel. (3,4) Low socioeconomic status, alcoholism, white race and male gender have been associated with high prevalence of *Strongyloides* infection. (5-9) Most infections are subclinical, although life-threatening internal autoinfection can occur in patients with compromised cellular immunity. (10,11)

Clinical symptoms range from asymptomatic or mild acute disease to chronic infection, with risk of disseminated

---

From Texas A&M University, Corpus Christi, Texas, USA (Salim Surani and Mauricio Rodriguez), University of Texas, Austin, Texas, USA (Sophia Nooruddin), and The University of Texas Health Science Center, Houston, The University of Texas Medical Branch at Galveston, The University of Texas, Houston, Texas, USA (Joseph Varon).

### Address for correspondence:

Salim Surani, MD  
613 Elizabeth Street, Suite 813  
Corpus Christi, Texas 78413, USA  
Email: srsurani@hotmail.com

infection and risk of development of hyperinfection syndrome. (12) Since the prevalence is low in developed countries, misdiagnosis and delayed diagnosis do occur in patients presenting with the strongyloidiasis, as it occurred in our case. (13)

*Strongyloides stercoralis* infection encompasses five clinical syndromes: i) acute infection with Löffler's syndrome; ii) chronic intestinal infection; iii) asymptomatic autoinfection; iv) symptomatic autoinfection; and the "hyperinfection" syndrome. (14) The most common manifestations of the hyperinfection include fever, nausea and vomiting, anorexia, diarrhea, abdominal pain, dyspnea, wheezing, hemoptysis, cough, pulmonary infiltrates. (15) It can be diagnosed by examination of stool and sputum. Unexpected diagnoses have been made by finding larvae in urine, ascitic fluid and blood smears.

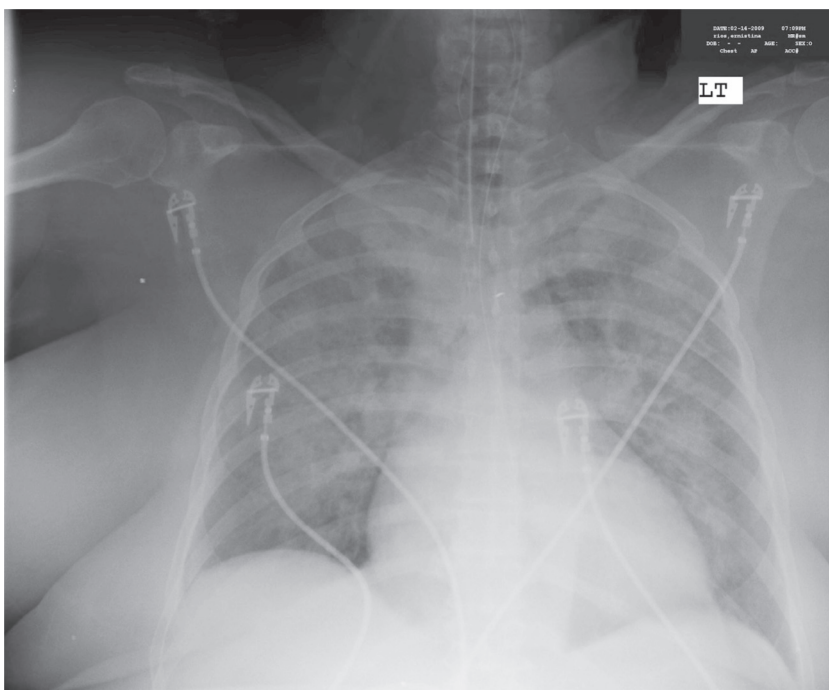
The hyperinfection syndrome is seen very commonly in

patients with immunocompromised status especially in patients with impaired cellular immunity. It is also commonly seen after steroid therapy or treatment with anti-TNF  $\alpha$  antibodies. Of all immunosuppressive drugs, glucocorticoids are the most widely associated with causing *Strongyloides* hyperinfection (as was the case in our patient). (16)

Limited guidelines exist in the prevention and management of *Strongyloides* infection in immunocompromised patients. Ivermectin is considered the drug of choice for most patients with strongyloidiasis, whereas thiabendazole and albendazole being alternatives.

Our patient was interesting and different in several aspects as the diagnosis was made by bronchoalveolar lavage (BAL), though initial BAL and open lung biopsy sample was negative for any larvae, whereas initiation of high dose steroid to treat bronchiolitis obliterans organizing pneumonia (BOOP), led to hyperinfection syndrome.

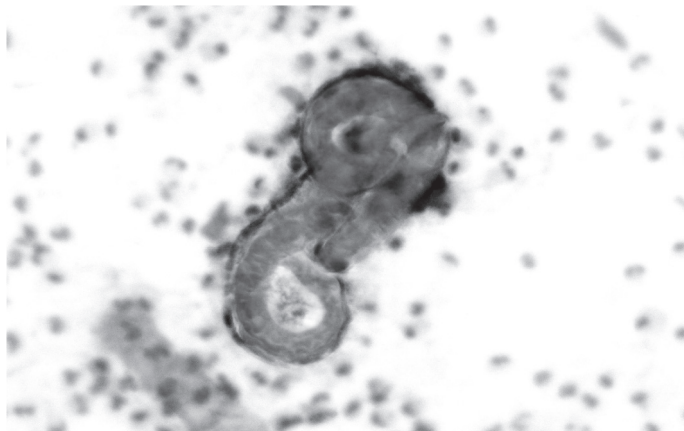
**Figure 1.** Portable chest X-ray revealing bilateral diffuse lung infiltrates



**Figure 2.** BAL showing filariform larvae of Strongyloides



**Figure 3.** BAL revealing Strongyloides larvae and polymorphonuclear neutrophils



## References

1. Danchenko N, Satia JA, Anthony I, Grove DI. Clinical manifestations. In: Grove R, editor. Strongyloidiasis: a major roundworm infection of man. Philadelphia (PA): Taylor & Francis; 1989. p. 1-9.
2. Genta RM. Global prevalence of strongyloidiasis: critical review with epidemiologic insights into prevention of disseminated disease. *Rev Infect Dis* 1989; 11:755-67.
3. Posey DL, Blackburn BG, Weinberg M, Flagg EW, Ortega L, Wilson M, et al. High prevalence and presumptive treatment of schistosomiasis and strongyloidiasis among African refugees. *Clin Infect Dis* 2007;45:1310-5.
4. Gyorkos TW, Genta RM, Viens P, MacLean JD. Seroepidemiology of Strongyloides infection in the Southeast Asian refugee population in Canada. *Am J Epidemiol* 1990;132:257-64.
5. Berk SL, Verghese A, Alvarez S, Hall K, Smith B. Clinical and epidemiologic features of strongyloidiasis. A prospective study in rural Tennessee. *Arch Intern Med* 1987;147:1257-61.
6. Davidson RA, Fletcher RH, Chapman LE. Risk factors for strongyloidiasis. A case-control study. *Arch Intern Med* 1984;144:321-4.
7. de Oliveira LC, Ribeiro CT, Mendes Dde M, Oliveira TC, Costa-Cruz JM. Frequency of Strongyloides stercoralis infection in alcoholics. *Mem Inst Oswaldo Cruz* 2002;97:119-21.
8. Walzer PD, Milder JE, Banwell JG, Kilgore G, Klein M, Parker R. Epidemiologic features of Strongyloides stercoralis infection in an endemic area of the United States. *Am J Trop Med Hyg* 1982;31:313-9.
9. Keiser PB, Nutman TB. Strongyloides stercoralis in the Immunocompromised Population. *Clin Microbiol Rev* 2004;17:208-17.
10. Mahmoud AA. Strongyloidiasis. *Clin Infect Dis* 1996;23:949-53.
11. Weller PF, Leder KL. Strongyloidiasis. [Online]. 2009 [cited 2009 Jun 22]. Available from: URL:<http://uptodateonline.com/online/content/topic.do?topicKey=parasite/4704&view=print>.
12. Vadlamudi RS, Chi DS, Krishnaswamy G. Intestinal strongyloidiasis and hyperinfection syndrome. *Clin Mol Allergy* 2006;4:8.
13. Boulware DR, Stauffer WM, Hendel-Paterson BR, Rocha JL, Seet RC, Summer AP, et al. Maltreatment of Strongyloides infection: case series and worldwide physicians-in-training survey. *Am J Med* 2007;120: 545-551.
14. Marcos LA, Terashima A, Dupont HL, Gotuzzo E. Strongyloides hyperinfection syndrome: an emerging global infectious disease. *Trans R Soc Trop Med Hyg* 2008;102:314-8.
15. Longworth DL, Weller PF. Hyperinfection syndrome with Strongyloidiasis. In: Remington JS, Swartz MN, editors. *Current clinical topics in infectious disease*. New York: McGraw-Hill; 1986. p. 1.
16. Fardet L, Génereau T, Cabane J, Kettaneh A. Severe strongyloidiasis in corticosteroid-treated patients. *Clin Microbiol Infect* 2006;12:945-7.