

Traumatic pneumomediastinum

James Tietjens, Ross Freebairn, Kate Law, Marianne Lill

Case presentation

A previously-healthy thirty-year old man presented to the Emergency Department at Hawke's Bay Hospital with central chest pain, following blunt chest trauma whilst SCUBA diving. He was at a depth of approximately five metres, during his ascent, when he was dumped onto a rock by a wave, hitting the left side of his chest. Several hours later, he developed central chest tightness and mild dyspnoea. He had no dysphagia or abdominal pain. Examination findings showed normal vital signs, reduced air entry over left chest wall, and a "crunchy" systolic murmur. He had subcutaneous emphysema around his neck. His trachea was central and non-tender. His abdomen was soft, and non-tender. Blood tests showed a mild leucocytosis, but were otherwise within normal

limits. CXR (Figure 1) showed pneumomediastinum, with no obvious pneumothorax. A subsequent computerised tomogram (CT) neck and chest (Figure 2) showed extensive pneumomediastinum, subcutaneous emphysema on both sides of neck, no pneumothorax, no tracheal disruption or lung pathology. He was admitted to the Intensive Care Unit and managed conservatively. He was placed on Optiflow™ Nasal Interface (© Fisher & Paykel Healthcare Corporation Limited, Panmure, Auckland, New Zealand) – which delivers high flow humidified oxygen via soft nasal prongs. Repeat CXR showed resolving pneumomediastinum and he was discharged after three days, with no known complications to date.

Discussion

Pneumomediastinum, also known as mediastinal emphysema, represents free air in the mediastinum. It can be spontaneous or secondary to trauma - including iatrogenic injury. Traumatic pneumomediastinum was first described in 1819, and occurs in up to 10% of patients

with severe blunt chest trauma. (1) This entity is not always detectable on chest radiograph (CXR) and may be asymptomatic. In the majority of cases it is a self-limiting condition. It may, however, have serious sequelae and is associated with other injuries.

From Hawke's Bay Hospital, Hastings, New Zealand (James Tietjens, Ross Freebairn, Kate Law, and Marianne Lill)

Address for correspondence:

James Tietjens
Hawke's Bay Hospital
Omahu Road
PO Box 9014
Hastings, New Zealand
Tel: 027-6641244
E-mail: j.titch@gmail.com

Figure 1. CXR showing pneumomediastinum

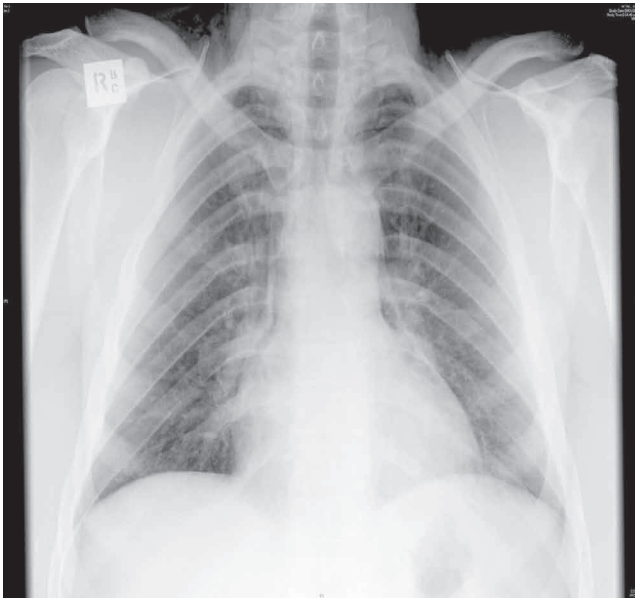
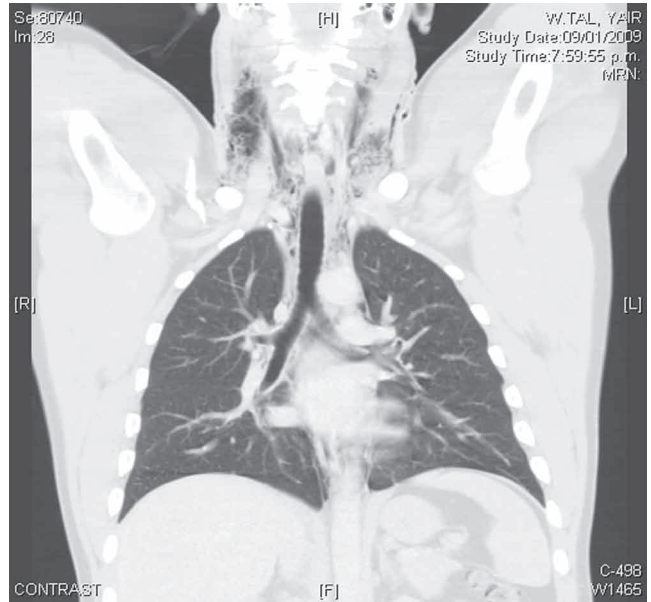


Figure 2. CT chest and neck showing pneumomediastinum and subcutaneous emphysema of neck



References

1. Dissanaik S, Shalhub S, Jurkovich GJ. The evaluation of pneumomediastinum in blunt trauma patients. *J Trauma* 2008;65:1340-5.