

Airway Pressure Release Ventilation (APRV) for the Treatment of Severe Life-Threatening ARDS in a Morbidly Obese Patient

Amyr Hirani, Rodrigo Cavallazzi, Anastasia Shnitser, Paul E. Marik

Abstract

Airway pressure release ventilation (APRV) is a novel mode of positive pressure ventilation that has a number of advantages over low-tidal volume, assist-control ventilation in patients with the acute respiratory distress syndrome (ARDS). APRV may

have particular utility in morbidly obese patients with respiratory failure. We report a case of a morbidly obese patient who developed aspiration pneumonitis and severe life threatening ARDS who was successfully managed with APRV.

Key words: ARDS, aspiration pneumonitis, surgery, anesthesia, aspiration, APRV, mechanical ventilation.

Airway pressure release ventilation (APRV) is a relatively new mode of ventilation that became commercially available in the United States in the mid-1990s. APRV differs fundamentally from that of conventional positive-pressure ventilation. Whereas conventional modes of ventilation begin the ventilatory cycle at a baseline pressure and elevate airway pressure to accomplish tidal ventilation, APRV commences at an elevated baseline pressure and follows with a deflation to accomplish tidal ventilation (**Figure 1**) [1]. The elevated baseline pressure facilitates oxygenation and lung recruitment while the timed releases aids in carbon dioxide removal. Advantages of APRV include lower airway pressures, lower minute ventilation, minimal adverse effects on cardio-circulatory function, ability to spontaneously breathe throughout the entire ventilatory cycle and decreased need for sedation.

APRV is consistent with lung protection strategies that strive to limit lung injury associated with mechanical ventilation. APRV is a recognized mode of ventilation in trauma patients with acute respiratory distress syndrome (ARDS) [2]. However, its adoption in the medical ICU has been limited. We report the case of a morbidly obese patient who developed aspiration pneumonitis and severe life-threatening ARDS who was successfully managed with APRV.

Case report

A 25 year-old African-American male presented to hospital for ophthalmic surgery for retinal detachment of his right eye. His past medical history was significant for asthma, morbid obesity (BMI of 53.2 kg/m²), and obstructive sleep apnea. During anesthesia his airway was “secured” with a laryngeal mask (LMA). In the immediate post-operative period, he developed respiratory distress which was treated with supplemental oxygen as well as methylprednisolone, furosemide, and nebulized bronchodilators. He was transferred to the medical intensive care unit (MICU) with respiratory distress, progressive hypoxemia and hypotension requiring fluid resuscitation and endotracheal intubation (approximately 6 hours after

From Thomas Jefferson University, Philadelphia, USA (Drs. Amyr Hirani, Rodrigo Cavallazzi, Anastasia Shnitser, and Paul E. Marik).

Address for correspondence:

Paul E. Marik, MD, FCCP, FCCM
Chief of Pulmonary and Critical Care Medicine
Thomas Jefferson University
834 Walnut Street, Suite 650, Philadelphia, PA, 19107, USA
Fax: 215 955-0830
Email: paul.marik@jefferson.edu

surgery) with assisted mechanical ventilation.

On presentation to the ICU his temperature was 98°F, heart rate 120 beats per minute, blood pressure 90/60 mmHg, respiratory rate 30 breaths per minute with an oxygen saturation of 88% on a rebreathing mask. Physical examination was notable for morbid obesity, coarse breath sounds on lung auscultation and bilateral lower extremity pitting edema. On admission white blood cell was $31 \times 10^9/l$ with 90% neutrophils, creatinine was 2.1 mg/dl and lactate was 6.7 mmol/l (67.4 mg/dl). Arterial blood gas analysis on assist-controlled ventilation with a tidal volume 750 ml (9 ml/kg ideal body weight of 80kg), respiratory rate of 20/minute, PEEP of 5 cmH₂O and FiO₂ of 1.0 was pH 7.22, PaCO₂ 58 mmHg and PaO₂ of 82 mmHg with an oxygen saturation of 94%. The chest radiograph revealed diffuse bilateral alveolar airspace disease (**Figure 2**). The presumptive diagnosis was acid aspiration pneumonitis causing ARDS (Mendelsohn's syndrome) [3]. The patient developed progressive hypoxia despite increasing PEEP to 16 cmH₂O with repeat blood gas analysis demonstrating a pH of 7.21, PaCO₂ of 49 mmHg, PaO₂ of 50 mmHg with an oxygen saturation of 84%. At this point the patient was switched to APRV (Puritan-Bennett 940® ventilator) with the following settings: PEEP-high 35 cmH₂O, PEEP-low 5 cmH₂O, release rate of 12/minute, time-low of 0.8 s, pressure support of 5 cmH₂O above PEEP-high and a FiO₂ of 100%. Within hours of changing to APRV we noted significant improvement in oxygenation, a decrease in dead space ventilation ratio from 0.7 to 0.46 (NICO® Vd/Vt) with minimal change in PaCO₂. Repeat chest radiograph was markedly improved (**Figure 3**). The change in the PaO₂/FiO₂ and PaCO₂ over time is illustrated in **Figure 4**.

A transthoracic echocardiogram demonstrated normal cardiac size and function while lower extremity venous Doppler examination was normal. Additional treatment included a hydrocortisone infusion at 10 cc/hr (for 7 days followed by a steroid taper), enoxaparin at prophylactic dose (40 mg SC daily) and enteral nutrition (Oxepa, Ross/Abbott Laboratories, Chicago, IL). Vancomycin and piperacillin/tazobactam initiated for treatment of presumed sepsis were discontinued

once the mini-bronchoalveolar lavage and all other cultures were negative. The patient had a prolonged stay in ICU, being liberated from mechanical ventilation after 13 days of APRV. The remainder of his hospital course was uneventful; he was discharged after 20 days of hospitalization.

Discussion

ARDS is a frequent cause of admission to the ICU. The current standard ventilatory mode for patients with ARDS is volume-controlled ventilation using a low-tidal volume lung protective strategy (6 ml/kg ideal body weight) [4]. In a subset of patients with severe ARDS such a ventilatory strategy may be unable to maintain adequate arterial oxygenation and ventilation. APRV has been used in trauma patients as a rescue mode to improve oxygenation in patients failing assist-control mode [2]. There is limited data on the use of APRV in medical patients with severe ARDS. APRV may be particularly useful in patient with morbid obesity. We believe that the use of APRV in our patient was a life saving intervention.

APRV, first described by Stock and Downs in 1987 [5], is a time-triggered, pressure-limited, time-cycled mode of ventilation that allows unrestricted spontaneous breathing throughout the entire ventilatory cycle. The patient's spontaneous breaths are unrestricted and independent of the ventilator cycle. APRV helps to meet the goals of ARDS management by maximizing alveolar recruitment [6] while limiting the trans-alveolar pressure gradient and barotrauma. APRV is very well tolerated by patients allowing minimal sedation with spontaneous breathing which improves V/Q mismatching and cardiac performance [7,8]. The reduced need for sedative agents as compared to other modes of advanced ventilation is a very important attribute of APRV, as the use of sedative agents has been linked to prolonged ICU stays, delirium and increased risk of complications.

Morbid obesity has significant effects on the respiratory system which impacts the ventilatory management of these patients. The expiratory reserve

volume (ERV) declines significantly with increasing BMI. The fall in ERV is presumably due to small airway closure particularly in the dependent areas of the lung. The vital capacity (VC), total lung capacity (TLC) and functional residual volume (FRV) are generally maintained in otherwise normal individuals with mild to moderate obesity but are reduced by up to 30% in morbidly obese patients [9-10]. In addition, the mechanical effect of obesity causes a decrease in chest wall compliance. The effects of obesity on the respiratory system are compounded in patients with acute lung injury, consequently the standard approach to ventilatory support with low-tidal volumes may result in severe lung derecruitment and inadequate ventilation. APRV may be the ideal ventilatory mode in obese patients with severe ARDS as the increased mean alveolar pressure with short release time will recruit collapsed lung while preventing over-distension of ventilated alveoli.

In our institution, we use a step-wise strategy to liberate patients from mechanical ventilation when on the APRV mode. First we decrease FiO_2 followed by the PEEP-high. Should the patient tolerate the decrease in FiO_2 and PEEP-high, we then increase time-low with further reductions in the PEEP-high until we reach a CPAP (PEEP-low) of 5 cmH_2O . At this point we increase the pressure support to 10 cmH_2O followed by extubation if the patient is comfortable on these settings. It is very important to stress that the PEEP-high should be reduced in increments of no greater than 3 cmH_2O at an interval no more frequently than every 8-12 hours. Severe (and irreversible) derecruitment may occur if PEEP-high is weaned to rapidly.

In summary, we believe that APRV should be considered in patients with severe ARDS who tolerate low-tidal volume assist controlled ventilation poorly. APRV may be particularly useful in the management of obese patients with ARDS.

Figure 1. TYPICAL PRESSURE WAVEFORM OF APRV

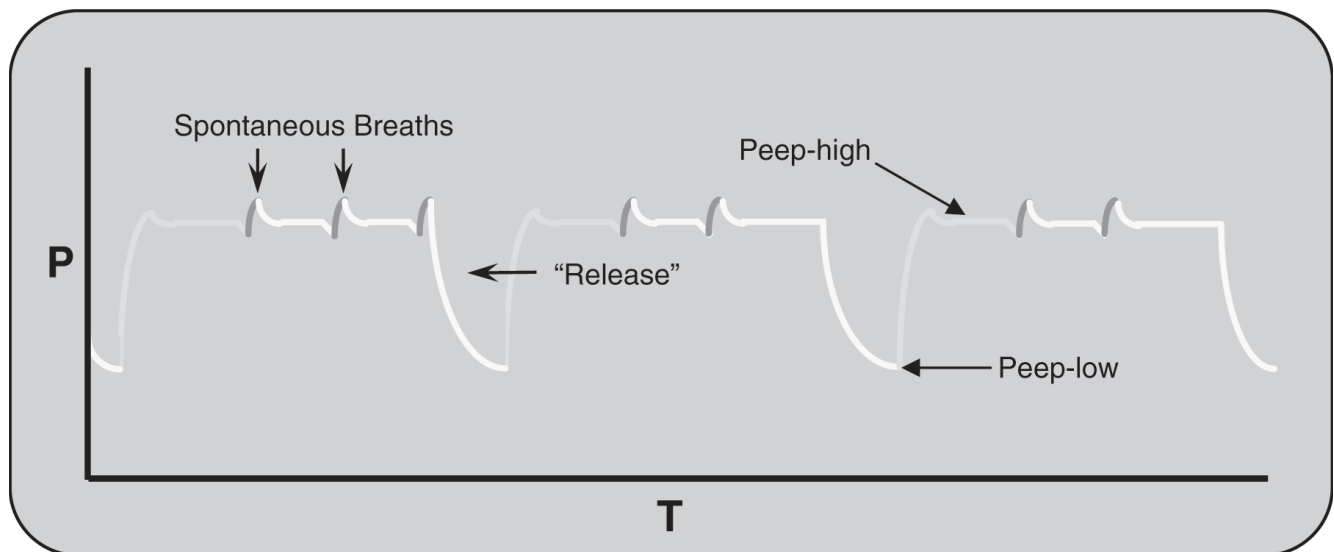


Figure 2. PRESENTING PORTABLE AP CHEST RADIOGRAPH

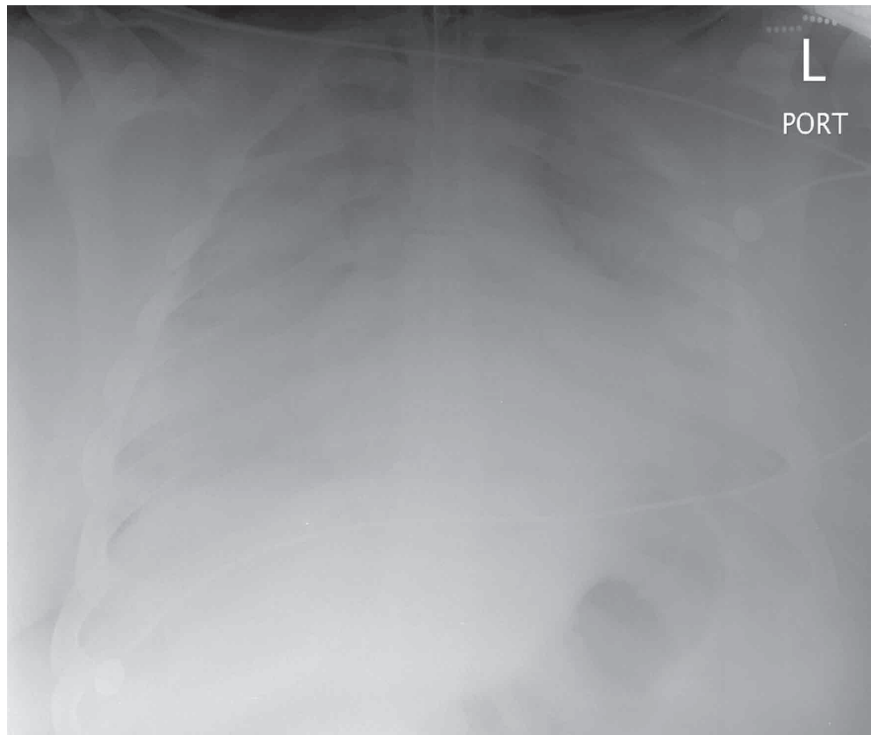


Figure 3. PORTABLE AP CHEST RADIOGRAPH ON DAY 2

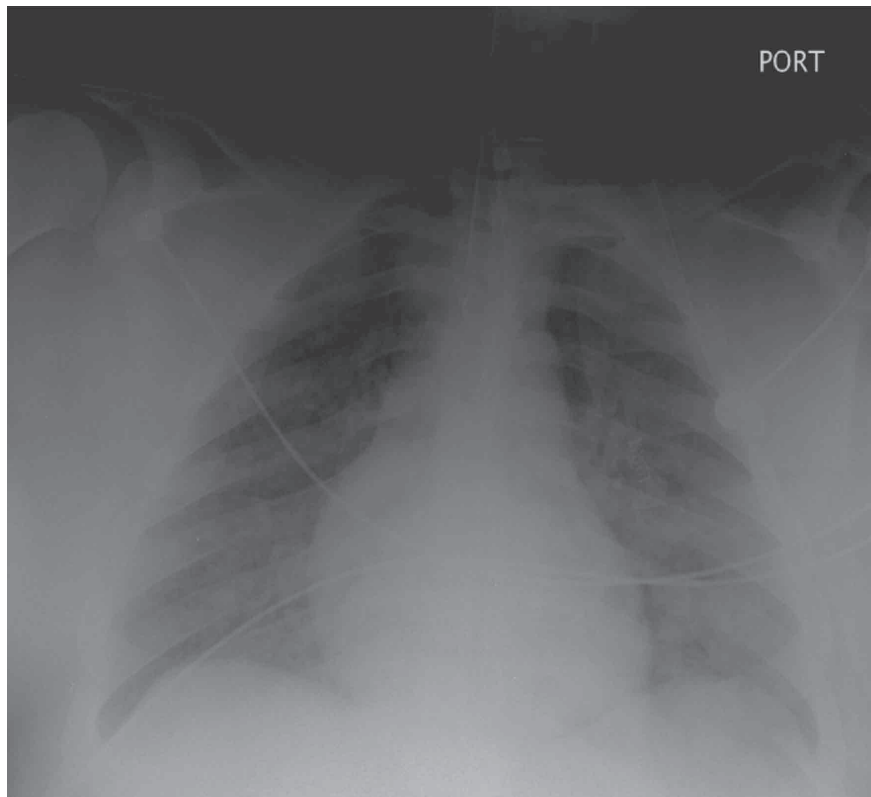
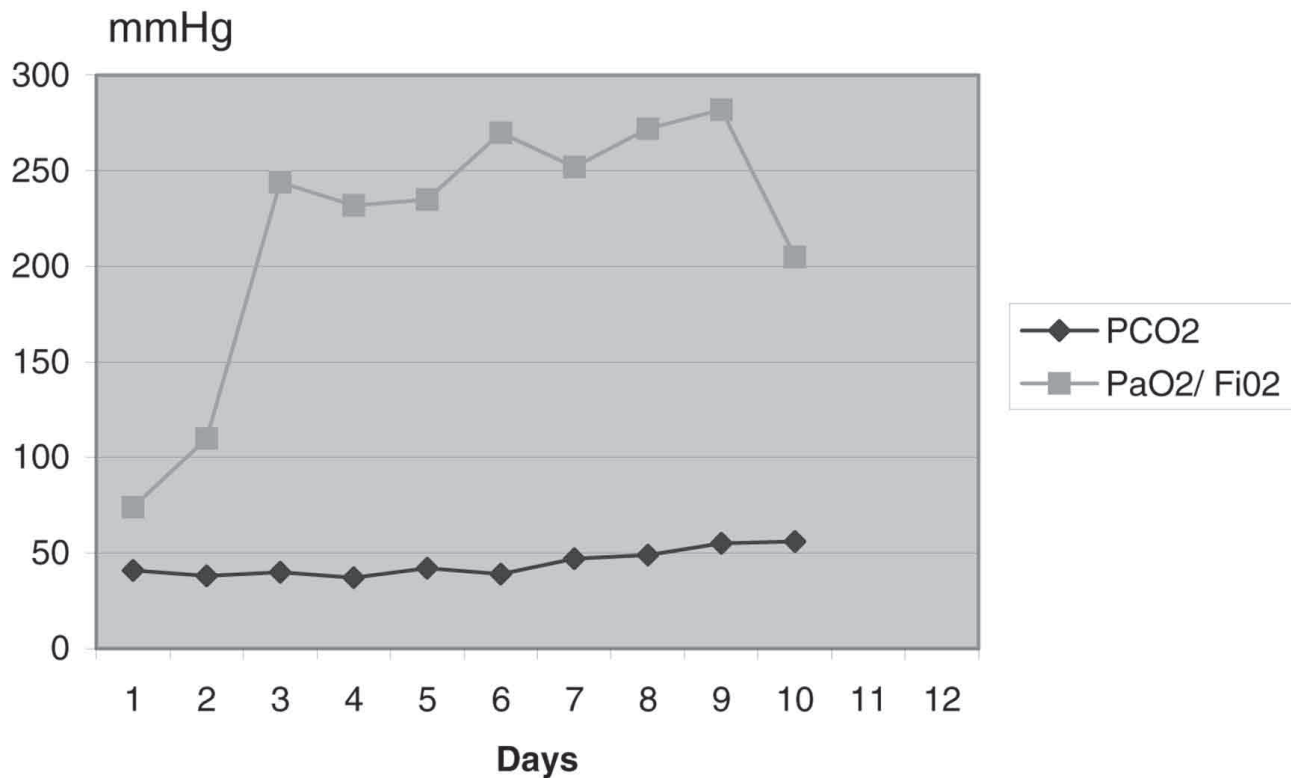


Figure 4. EFFECT OF APRV OF PaO₂/FiO₂ AND PaCO₂ OVER TIME



References

1. Frawley PM, Habashi NM (2001) Airway pressure release ventilation: theory and practice. AACN Clin Issues 12:234-246
2. Dart BW 4th, Maxwell RA, Richart CM, Brooks DK, Ciraulo DL, Barker DE, Burns RP (2005) Preliminary experience with airway pressure release ventilation in a trauma/surgical intensive care unit. J Trauma 59:71-76
3. Marik PE (2001) Aspiration pneumonitis and aspiration pneumonia. N Engl J Med 344:665-671
4. (2000) Ventilation with lower tidal volumes as compared with traditional tidal volumes for acute lung injury and the acute respiratory distress syndrome. The Acute Respiratory Distress Syndrome Network. N Engl J Med 342:1301-1308
5. Downs JB, Stock MC (1987) Airway pressure release ventilation: a new concept in ventilatory support. Crit Care Med 15:459-461
6. Sydow M, Burchardi H, Ephraim E, Zielmann S, Crozier TA (1994) Long-term effects of two different ventilatory modes on oxygenation in acute lung injury. Comparison of airway pressure release ventilation and volume-controlled inverse ratio ventilation. Am J Respir Crit Care Med 149:1550-1556
7. Putensen C, Mutz NJ, Putensen-Himmer G, Zinslerling J (1999) Spontaneous breathing during ventilatory support improves ventilation-perfusion distributions in patients with acute respiratory distress syndrome. Am J Respir Crit Care Med 159:1241-1248
8. Kaplan LJ, Bailey H, Formosa V (2001) Airway pressure release ventilation increases cardiac performance in patients with acute lung injury/adult respiratory distress syndrome. Crit Care 5:221-226
9. Marik P, Varon J (1998) The obese patient in the ICU. Chest 113:492-498
10. Varon J, Marik P (2001) Management of the obese critically ill patient. Crit Care Clin 17:187-200