

Recombinant Human Activated Protein C in Neurocritical Care: Case Series and Literature Review of Spinal Cord Injury, Severe Sepsis and Recombinant Human Activated Protein C Therapy

Rosángela L. Fernández-Medero, Angel Cestero-Ruiz, Ricardo H. Brau-Ramírez, William Rodríguez-Cintrón, Gloria Rodríguez-Vega

Abstract

Spinal cord injury (SCI) is a serious condition that produces lifelong disabilities, with only limited therapeutic measures currently available. The incidence of SCI in the United States is estimated to be 30-40 cases per one million inhabitants, with resultant in-hospital mortality of 20 to 52 percent. (1,2) Traumatic SCI is followed by a progressive injury process that involves various pathophysiological events that lead to tissue destruction. Although the mechanisms are not fully understood, progressive vascular events, such as ischemia/reperfusion-induced endothelial damage, are involved in this process. As in sepsis, studies have demonstrated that activated

neutrophils are important in inducing the damage to endothelial cells. (3) A common complication in patients with SCI is sepsis, which is associated with acute organ dysfunction, and results in a generalized inflammatory and procoagulant state. Sepsis is a major cause of death in intensive care units worldwide, with mortality rates that range from 20% for sepsis to 40% for severe sepsis to >60% for septic shock, that if related to SCI may be aggravated with concomitant spinal shock. We describe our experience with recombinant human activated protein C (rhAPC) in patients with SCI and severe sepsis (SS).

Key words: Neurocritical care, recombinant human activated protein C, septic shock, severe sepsis, spinal cord injury.

From Neurosurgery Intensive Care Unit at University District Hospital, University of Puerto Rico, Medical Sciences Campus, School of Medicine, San Juan, Puerto Rico (Angel Cestero-Ruiz, Ricardo H. Brau-Ramírez, and Gloria Rodríguez-Vega) and VA Caribbean Healthcare System, Pulmonary and Critical Care Medicine Section, Pulmonary and Critical Care Medicine Fellowship Program, San Juan, Puerto Rico (Rosángela L. Fernández-Medero and William Rodríguez-Cintrón)

Address for correspondence:

Rosángela L. Fernández-Medero
VA Caribbean Healthcare System
10 Casia St., San Juan, Puerto Rico 00921
Email: fernandezmedero@yahoo.com

Introduction

Spinal cord injury (SCI) is an uncommon but expensive condition to treat. In the United States, there are approximately 40 new cases per million people each year. This corresponds to approximately 11,000 new cases per year. Currently, it is estimated that the prevalence of SCI in the United States is approximately 800 cases per million population, corresponding to about 220,000 nationwide. One common complication in these patients is sepsis, mainly related to decubitus ulcers and ventilator associated pneumonia. (4) The incidence of sepsis and the number of sepsis-related deaths are increasing, although the overall mortality rate among patients with sepsis is declining. (5-8)

Severe sepsis (SS) contributes to approximately 10 percent of admissions to the intensive care unit worldwide. (9) In the United States, sepsis is the leading cause of death in non-coronary ICU patients, and the tenth most common cause of death overall, according to data from the Centers for Disease Control and Prevention. (10) In Puerto Rico sepsis is a significant cause of morbidity and mortality as well. (11) SS accounts for 10-28% of admissions to the ICU, is associated with an unacceptably high hospital mortality of 30-50%, and consumes considerable resources. (12,13) It is common and also more dangerous in elderly, immunocompromised, and critically ill patients, including neurocritically ill patients. It occurs in 1%-2% of all hospitalizations and accounts for as much as 25% of intensive care unit (ICU) bed utilization. According to epidemiological data in Puerto Rico, sepsis is the thirteenth cause of death, and its mortality is approximately 56%. (9,12,13)

Among the therapeutic regimens for sepsis, recombinant human activated protein C (rhAPC) has antithrombotic, antiinflammatory, and profibrinolytic properties. Studies have shown that rhAPC produced dose-dependent reductions in the levels of markers of coagulation and inflammation and mortality in patients with severe sepsis. (12,13) In 2001, the Food and Drug Administration (FDA) approved rhAPC (Xigris®, Eli Lilly) for the treatment of patients with severe sepsis who have a high risk of death. (8) However, there is no data about the use of rhAPC in neurocritically ill patients, including patient with SCI with severe sepsis. (14) The use of rhAPC for SS in patients with SCI is a controversial one due to the possible increased risk of bleeding in such patients. We describe the clinical course of three patients with SCI complicated with SS that received rhAPC at the University District Hospital in San Juan, Puerto Rico.

Case Reports

Case 1

A 46-year-old man with prior medical history of depression, arrived to the Emergency Department (ED) after suffering a fall with cervical trauma. His physical exam was remarkable for a Glasgow Coma Scale (GCS) 15, and absent motor and

sensory function. He was admitted to the neurosurgical service with a diagnosis of C4-C5 herniated nucleus pulposus with cervical stenosis, spinal cord contusion (**Figure 1**), and quadriplegia. The patient was started on IV steroids, and scheduled for surgery. On the 10th hospital day, he was diagnosed with a urinary tract infection, initiated on IV fluoroquinolone, and the surgery postponed. Cervical dissection was scheduled 13 days after admission, and after the skin incision was done, he presented with desaturation episodes and increased peak airway pressures, requiring 100% oxygen and high PEEP levels. The surgical procedure was aborted and the patient was transferred to the Neurosurgical Intensive Care Unit (NSICU), where pulmonary embolism was initially ruled out. The diagnosis of septic shock and ARDS due to hospital acquired pneumonia was made, and therapy with intravenous fluids (IVFs), lung protective mechanical ventilation, high dose vasopressors, intensive insulin therapy and broad spectrum antibiotics was administered. He also developed critical illness-related corticosteroid insufficiency (CIRCI) and acute renal failure. Since he was considered at high risk of death, rhAPC therapy was initiated 12 hours postoperatively without complications at 24 mcg/kg/hour for 96 hours. The patient completed IV antibiotics therapy satisfactorily, weaned off vasopressors, recovered renal function, and was placed on Adaptive Support Ventilation (ASV) for weaning process. After clinical improvement the patient was extubated, initiated on a rehabilitation program, and discharged home 3 months later.

Although his APACHE score was 24, he was at high risk for death as evidenced by four organ failure, (15-17) and did not present an absolute contraindication to rhAPC. Therefore, after discussion with the attending neurosurgeon, it was clarified that only a skin incision was done intraoperatively and spinal surgery was not performed. For this reason, an extensive review of the patient's clinical condition with staff physicians, neurosurgeons and relatives was done. Discussion included the clarification regarding absence of spinal hematoma by imaging studies and no recent spinal surgery, so the family was oriented about benefits and risks of therapy with rhAPC. Also they all were oriented about rhAPC indications, usage, adverse reactions, warnings, relative and absolute contraindications, and the therapy was completed with positive outcomes.

Case 2

A 79-year-old man with pertinent medical history for hypertension, diabetes mellitus type 2, atrial fibrillation, and prostatectomy secondary to cancer arrived to the ED with a cervical C5-C6 subluxation (**Figure 2**) and quadriplegia secondary to motor vehicle accident (MVA). After the neurosurgical evaluation, a dislocation reduction with traction was done. The patient's condition deteriorated with hypotension and bradycardia consistent with neurogenic shock, requiring endotracheal intubation and mechanical ventilation, IVFs hydration, and IV vasopressors. He was transferred to the NSICU in neurogenic shock, where a transcutaneous pacemaker was placed. On the fourth day of admission, he developed tachycardia, leucopenia, and lactatemia. Assessment of SS secondary to ventilator associated pneumonia was done. Broad spectrum IV antibiotics were added to his therapeutic regimen in addition to IVFs and vasopressors agents. Also CIRCI was ruled out with a random cortisol level. At this time rhAPC was not considered due to concerns about possible spinal cord contusion, and increased risk of bleeding. Approximately 36 hours later, his clinical condition had deteriorated with MODS and ARDS requiring lung protective mechanical measures, despite which his condition was complicated with barotrauma and subcutaneous emphysema requiring bilateral chest tube placement. The APACHE score was calculated at 30. After discussing with the neurosurgical attending, it was determined that at this point he was not at increased risk of bleeding, and was initiated on rhAPC infusion without complications. After the rhAPC infusion at 24 mcg/kg/h for 96 hours, the patient was weaned off vasopressors successfully. However, he continued with neurologic deterioration and died with refractory neurogenic shock 2 months later, despite therapy with IVFs, intensive insulin therapy, low volume mechanical ventilation, vasopressors and steroid replacement therapy.

This patient completed satisfactorily the rhAPC infusion therapy, with short term initial recovery from septic shock, as evidence by improvement in clinical status, hemodynamics parameters and oxygenation. The therapeutic goal was to provide the benefits of rhAPC therapy, in the absence of absolute contraindications in a patient at high risk of death. Extensive discussion with family including rhAPC indications, usage, adverse reactions, and contraindications

was done. Since the benefits outweighed the risks, they agreed with the therapeutic regimen.

Case 3

An 84-year-old man with medical history of diabetes mellitus type 2, dyslipidemia, and rheumatoid arthritis was transferred to our institution with a 2 week history of weakness that progressed to quadriplegia. He was admitted to NSICU with the diagnosis of cervical stenosis and spinal cord compression (**Figure 3**) and was initiated on IV steroids. Upon initial evaluation he was also found with sepsis secondary to a urinary tract infection and therapy with IV fluoroquinolone was given. The patient was not considered a candidate for surgery after extensive case analysis, and risks and benefits evaluation. On the second day of admission, he progressed to SS with oliguric acute renal failure, disseminated intravascular coagulation (DIC), lactatemia, and abnormal elevation of liver enzymes. Sepsis induced cholecystitis was suspected, so the patient was treated with aggressive IVFs resuscitation, broad spectrum IV antibiotics, intensive insulin therapy, and CIRCI was ruled out. An APACHE score of 30 and the presence of SS favored the use of rhAPC in this case. The infusion was administered for 96 hours at 24 mcg/kg/h without complications. On his third hospital day, the patient experienced a significant improvement of his renal function, resolution of lactatemia and normalization of liver enzymes and coagulation parameters. After completion of seven days of IV antibiotics therapy, he was transferred to another institution to continue supportive and conservative therapy.

In view of no absolute contraindications, and considering that the clinical deterioration was mainly due to SS, rhAPC was administered after the patient and his next of kin were explained about benefits and risks of therapy. Fortunately, in this case therapy was successfully completed with positive outcomes.

Discussion

SCI occurs at a rate of 30 to 40 per one million population per year, resulting in approximately 10,000 new cases

each year. The prevalence of SCI is over 200,000. SCI occurs primarily in young males 18 to 25 years of age. The primary precipitant of injury is MVA, although in some areas, swimming and diving-related accidents may take precedence. Sports-related injuries account for less than 5% of the total. SCI rarely occurs in isolation, and over 75% of these patients have some other systemic injury. (18,19) Ischemia is a very prominent feature of post-SCI events, and there is a significant reduction in spinal cord blood flow, which may be confounded by loss of the normal autoregulatory response of the spinal cord vasculature. This may be worsened if related to sepsis since the pathophysiology of sepsis is caused by unrestricted or inappropriate coagulation in the microcirculation. (5-8,20) SCI is a serious condition that produces lifelong disabilities. Only limited therapeutic measures are currently available for its treatment. SCI induced by trauma is a consequence of an initial physical insult that is followed by a progressive injury process that involves various pathochemical events that lead to tissue destruction. Therapeutic intervention for SCI should therefore be directed at reducing or alleviating this secondary process. Although the mechanisms are not fully understood, progressive vascular events, such as ischemia/reperfusion-induced endothelial damage, are involved in this process. As in sepsis, studies have demonstrated that activated neutrophils are important in inducing the damage to endothelial cells observed in SCI induced by trauma (19,20).

SS, defined as sepsis associated with acute organ dysfunction, results from a generalized inflammatory and procoagulant response to an infection. The rate of death from SS ranges from 30 to 50 percent despite advances in critical care. In the United States, approximately 750,000 cases of sepsis occur each year, at least 225,000 of which are fatal. This is characterized by inflammatory cytokines, including tumor necrosis factor and interleukins, are capable of activating coagulation and inhibiting fibrinolysis, whereas the procoagulant thrombin is capable of stimulating multiple inflammatory pathways. (14) The end result is a diffuse endovascular injury, multiorgan dysfunction, and death. Considering the changes associated to SCI, patients in the NSICU, as described, benefit of aggressive therapy when a sepsis syndrome develops.

Studies have revealed that the mechanism of action of

rhAPC includes fibrinolysis and reduction in the coagulation and inflammation associated with SS. It is converted from its inactive precursor, protein C, by thrombin coupling to thrombomodulin. The conversion of protein C to activated protein C may be impaired during sepsis as a result of the down-regulation of thrombomodulin by inflammatory cytokines. Reduced levels of protein C are found in the majority of patients with sepsis and are associated with an increased risk of death. Previous preclinical and clinical studies showed that the administration of activated protein C improve outcomes in SS. (14,20) In a previous study, rhAPC produced dose-dependent reductions in the levels of markers of coagulation and inflammation in patients with SS. Treatment with rhAPC was associated with a significant reduction in mortality. (12,13)

The rhAPC is the first biologic agent approved in the United States for the treatment of SS. Its' success came after almost two decades of intensive research and more than 20 large clinical trials of other candidate therapeutics. As is the case with other anticoagulants, it may cause serious hemorrhage, and the risk of this complication needs to be assessed in the context of the potential benefit of the drug. (15-17) Obviously, there is an increased risk of bleeding in patients at the NSICU depending on the diagnosis, which includes patients with SCI. Certain conditions are likely to increase the risk of bleeding with rhAPC therapy. Therefore, for patients with SS this risk must be carefully considered when deciding whether to use this therapy. Our patients did not present absolute contraindications which included active thromboembolic event with concurrent heparin, recent anticoagulation therapy, thrombocytopenia less than $30 \times 10^9/L$, intracranial malformation or aneurysm, recent GI bleeding or stroke, severe hepatic disease, $INR > 3$ and bleeding diathesis. (12,13) In our experience rhAPC therapy was given safely, and our patients did not present bleeding complications.

The antiinflammatory activity of drotrecogin alfa activated may be mediated indirectly through the inhibition of the generation of thrombin, which leads to decreased activation of platelets, neutrophils recruitment, and mast cells degranulation. Furthermore, studies have demonstrated that APC has direct anti-inflammatory properties, including the inhibition of neutrophil activation, the cytokines production by lipopolysaccharide-challenged monocytes,

and E-selectin-mediated adhesion of cells to vascular endothelium, but the use in patients with SCI had not been previously reported. (2,3,14)

The biologic activity of rhAPC was demonstrated by the finding of greater decreases in D-dimer and interleukin-6 levels in patients who received therapy versus those who received placebo. (2,3) The higher incidence of serious bleeding during infusion in the drotrecogin alfa activated group is consistent with the antithrombotic activity of the drug and occurs predominantly in patients with a predisposition to bleeding. In patients with SS, an intravenous rhAPC at a dose of 24 mcg/kg/hour for 96 hours had been associated with a significant reduction in mortality and a safety profile that was acceptable within the context of this clinical trial. (14)

Considering the theory that rhAPC could also lessen the neurologic deficits in patients with SCI, these may suggest that a single therapeutic agent may help in the therapy of two different conditions. Our patients' clinical course may be the first step to develop prospective research of patients with SS and SCI that may confirm that rhAPC may not only help with SS, but also may reduce the deleterious effects of SCI.

Several animal studies showed that APC reduced the ischemia/reperfusion-induced SCI by inhibiting neutrophil activation. (2) The therapeutic mechanisms of APC might depend on its inhibitory effect on the production of TNF- α , which is a potent activator of neutrophils. Although the anticoagulant effects of APC might not be related to its ability to inhibit TNF- α production, its serine protease activity appears to be essential in the therapeutic mechanism. Thus, it is possible that APC may be effective in reducing ischemia/reperfusion-induced SCI in which activated neutrophils play an important role. It is possible that APC may also prevent the secondary effects of trauma-induced SCI by inhibiting neutrophil activation as suggested. (2,3)

The potentially neuroprotective effect of rhAPC has also been shown in two rat studies, (2,3,21,22), both of which suggested inhibition of leukocyte activation as an important mechanism. In one of these studies, (3,21) APC was shown to reduce motor disturbance resulting from SCI by reducing local levels of TNF- α , thereby inhibiting neutrophil

accumulation. In the other study, (3,22) animals treated with APC were found to have a reduction in ischemia and reperfusion induced renal injury, which was associated with reductions in renal levels of TNF- α , interleukin-8 and myeloperoxidase, with resulting inhibition of leukocyte activation. (2,3)

In animals' models, the goal was to determine whether APC can also prevent post-traumatic SCI, a condition in which leukocytes play an important role, so the investigators tested the effects of APC on SCI induced in rats by compression trauma. Administration of APC, either before or after the induction of SCI, markedly reduced the motor disturbances in these animals. In contrast, neither an inactive derivative of activated factor X called DEGR-Xa, a selective inhibitor of thrombin generation, nor active site-blocked APC denominated DIP-APC reduced the motor disturbances. In that study, histological examination revealed that intramedullary hemorrhages, observed 24 hr after trauma, were significantly reduced in the animals administered APC. The increase in the tissue level of TNF- α and the accumulation of neutrophils in the damaged segment of the spinal cord were significantly inhibited in the animals that had received APC, but these were not inhibited in those administered DIP-APC or DEGR-Xa. The induction of leukocytopenia had the same effect as APC, in that it significantly reduced motor disturbances, tissue levels of TNF- α , and neutrophil accumulation in the animals subjected to compressive SCI. (2)

These findings suggest that in SCI, APC reduces motor disturbances primarily by reducing the amount of TNF- α at the site of injury, thus inhibiting neutrophil accumulation and the resultant damage to the endothelial cells. They concluded that APC can lessen the severity of the trauma induced SCI by inhibiting the accumulation of neutrophils and the production of TNF- α .

To our knowledge, there is no data about the use of rhAPC in patients at the NSICU, including patients with SCI and SS. We described the clinical course and therapy with rhAPC in patients with SCI complicated with SS and septic shock. We consider this may be the first step in developing studies to confirm the findings that suggest that APC may lessen the severity of the SCI induced by trauma and the mechanism of SS, by inhibiting the accumulation of neutrophils and the

production of TNF- α , as described in animal studies. (2,3)

Conclusions

Very few data exist on regarding to the impact of the use of rhAPC in patients with SCI and SS. The entire sepsis syndrome represents a complex balance of proinflammatory and anti-inflammatory cytokines, and that some of the participants are, almost certainly, yet undiscovered. There is no published clinical data about the neuroprotective effects of rhAPC in patients with sepsis syndrome being admitted to a NSICU due to SCI.

rhAPC reduces endotoxin induced organ failures in experimental animals, such as coagulation abnormalities, pulmonary vascular injury, and hypotension. (2,3) These therapeutic effects cannot be exclusively due to its anticoagulant effects, but also are due to inhibition of TNF- α production. Administration of human plasma-derived APC ameliorated coagulation abnormalities without any adverse effects in patients with DIC. Studies strongly suggest that APC plays an important role in regulating inflammation by inhibiting both inflammatory responses and coagulation abnormalities through inhibition of TNF- α production by monocytes. It has also shown neuroprotective effect in patient with SCI as well. (2,3,23)

Our patients' clinical courses were adequate and without complications associated to APC therapy. There was clinical evidence of improvement regarding the sepsis syndrome,

and all patients were able to complete the infusion without complications. More accurate data on SS in neurocritical care is needed. For the future, it would be helpful for critical care physicians and scientific researchers, to further evaluate the efficiency of therapeutic trials with rhAPC in SCI and SS in patient such as ours.

This has enormous implications because the neurocritical care units' population is aging, and at high risk of sepsis syndrome, and it may be concluded that elderly patients admitted to neurocritical care units represent a distinct and important subgroup of patients. However, we could suggest that severely ill neurocritical care patients with SCI complicated with sepsis may benefit from the use of this therapy. This case series may be the first step to develop more research regarding SS and SCI, and the use of rhAPC in patient at high risk of death. The use of rhAPC for SS in patients with acute brain or spine cord injury is a controversial one due to the possible increased risk of bleeding in such tissues. We described three cases in which we used this valuable medication without induced bleeding, which is a feared complication, reason by which this medication is generally avoided at least in the early period after injury.

The best we can conclude is that two of our patients had good neurological outcome and that this raises the issue as to whether rhAPC may improve neurological outcome in humans, as well. These may lead to the theory that a single therapeutic agent may help in the therapy of two challenging conditions in the NSICU, such as SS and SCI, however still more research is needed.

Figure 1. Cervical MRI Showing Cervical Stenosis Due to C4-5 Herniated Nucleus Pulposus (Arrow) After Motor Vehicle Accident.

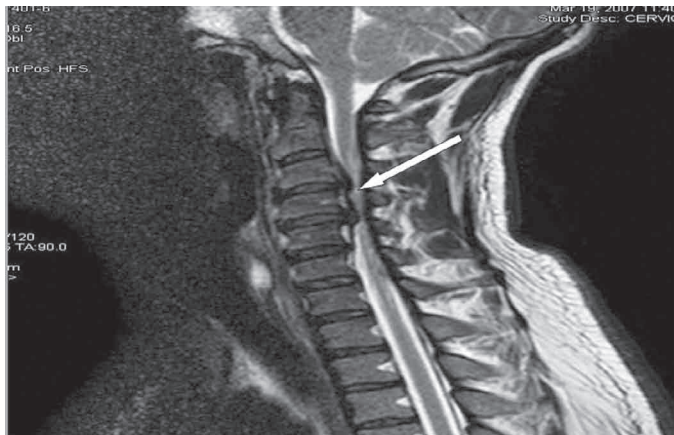


Figure 2. Cervical CT Scan Showing C5-6 Subluxation After Neck Trauma.

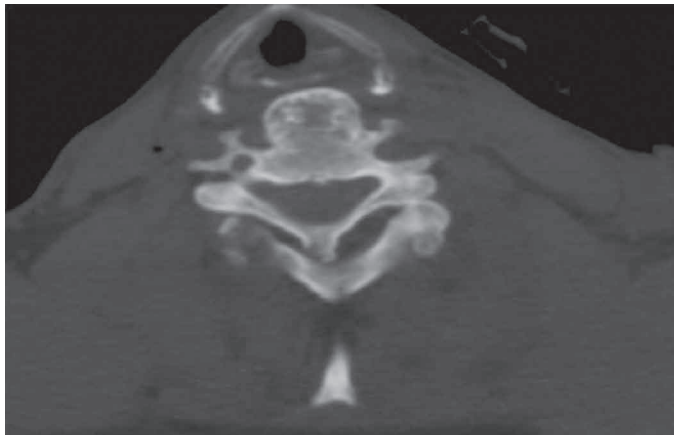
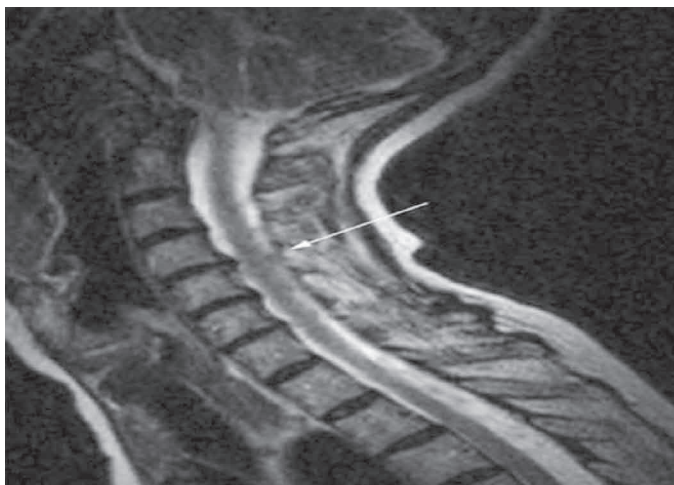

Figure 3. Cervical MRI Showing Cervical Stenosis (Not from Actual Patient).



References

1. Anish Bhardwaj, Marek A. Mirski, John A. Ulatowski. Spinal cord injury and related diseases. In: Tomas P. Bleck, editor. Handbook of Neurocritical Care. 1st ed. Totowa (NJ): Humana Press Inc; 2004. p. 165-182.
2. Taoka Y, Okajima K, Uchiba M, Murakami K, Harada N, Johno M, et al. Activated protein C reduces the severity of compression-induced spinal cord injury in rats by inhibiting activation of leukocytes. *J Neurosci* 1998;18:1393-8.
3. Hirose K, Okajima K, Taoka Y, Uchiba M, Tagami H, Nakano K, et al. Activated protein C reduces the ischemia/reperfusion-induced spinal cord injury in rats by inhibiting neutrophil activation. *Ann Surg* 2000;232:272-80.
4. Chan JW, Virgo KS, Johnson FE. Hemipelvectomy for severe decubitus ulcer in patient with previous spinal cord injury. *Am J Surg* 2003;185:69-73.
5. Spinal cord injury: facts and figures at a glance. *J Spinal Cord Med* 2000;23:153-5.
6. Marshall LF. Epidemiology and cost of central nervous system injury. *Clin Neurosurg*. 2000;46:105-12.
7. Burney RE, Maio RF, Maynard F, Karunas R. Incidence, characteristics, and outcome of spinal cord injury at trauma centers in North America. *Arch Surg* 1993;128:596-9.
8. Tator CH, Duncan EG, Edmonds VE, Lapczak LI, Andrews DF. Changes in epidemiology of acute spinal cord injury from 1947 to 1981. *Surg Neurol* 1993;40:207-15.
9. Abraham E, Laterre PF, Garg R, Levy H, Talwar D, Trzaskoma BL. Drotrecogin alfa (activated) for adults with severe sepsis and a low risk of death. *N Engl J Med* 2005;353:1332-41.
10. Centers for Disease Control and Prevention. National Center for Health Statistics. [Online]. [?] [cited 2007 Dec 19]; Available from: URL:<http://www.cdc.gov/nchs/ppt/icd9/icd1101d.ppt/>.
11. Publications from Department of Health, Puerto Rico. [Online]. [?] [cited 2007 Jan 21]; Available from: URL:<http://www.tendenciaspr.com/Salud/Salud.html/>.
12. Bernard GR, Vincent JL, Laterre PF, LaRosa SP, Dhainaut JF, Lopez-Rodriguez A, et al. Efficacy and safety of recombinant human activated protein C for severe sepsis. *N Engl J Med* 2001;344:699-709.
13. Laterre PF, Wittebole X. Clinical review: Drotrecogin alfa (activated) as adjunctive therapy for severe sepsis – practical aspects at the bedside and patient identification. *Crit Care* 2003;7:445-50.
14. Knaus WA, Draper EA, Wagner DP, Zimmerman JE. APACHE II: a severity of disease classification system. *Crit Care Med* 1985;13:818-29.
15. Glance LG, Osler TM, Papadakos P. Effect of mortality rate on the performance of the Acute Physiology and Chronic Health Evaluation II: a simulation study. *Crit Care Med* 2000;28:3424-8.
16. Markgraf R, Deuschinoff G, Pientka L, Scholten T. Comparison of acute physiology and chronic health evaluations II and III and simplified acute physiology score II: a prospective cohort study evaluating these methods to predict outcome in a German interdisciplinary intensive care unit. *Crit Care Med* 2000;28:26-33.
17. Evans RW, Wilberger JE, Bhatia S. Traumatic disorders. In: Goetz CG, editor. Textbook of clinical neurology. 3rd ed. Saunders; 2007. p. 1185-1212.
18. Lobosky J. The epidemiology of spinal cord injury. In: Narayan RK, Wilberger JE, Povlishok JT, editors. Neurotrauma. New York: McGraw-Hill; 1996.
19. Warren HS, Suffredini AF, Eichacker PQ, Munford RS. Risks and benefits of activated protein C treatment for severe sepsis. *N Engl J Med* 2002;347:1027-30.
20. Bajaj SP, Rapaport SI, Prodanos C. A simplified procedure for purification of human prothrombin, factor IX and factor X. *Prep Biochem* 1981;11:397-412.
21. Nesheim ME, Kettner C, Shaw E, Mann KG. Cofactor dependence of factor Xa incorporation into the prothrombinase complex. *J Biol Chem* 1981;256:6537-40.
22. Okajima K. Regulation of inflammatory responses by activated protein C. *International Congress Series* 2003;1255:17-23.